

# Mammographic Tumor Features Can Predict Long-Term Outcomes Reliably in Women with 1–14-mm Invasive Breast Carcinoma

## *Suggestions for the Reconsideration of Current Therapeutic Practice and the TNM Classification System*

Laszlo Tabar, M.D.<sup>1</sup>  
 Hsiu-Hsi Tony Chen, Ph.D.<sup>2</sup>  
 M. F. Amy Yen, M.Sc.<sup>3,4</sup>  
 Tibor Tot, M.D.<sup>5</sup>  
 Tao-Hsin Tung, M.S.<sup>2</sup>  
 Li-Sheng Chen, Ph.D.<sup>2</sup>  
 Yueh-Hsia Chiu, M.S.<sup>2</sup>  
 Stephen W. Duffy, M.Sc.<sup>3</sup>  
 Robert A. Smith, Ph.D.<sup>6</sup>

<sup>1</sup> Mammography Department, Central Hospital, Falun, Sweden.

<sup>2</sup> Graduate Institute of Preventive Medicine, National Taiwan University, Taipei, Taiwan.

<sup>3</sup> Cancer Research UK Department of Epidemiology, Mathematics, and Statistics, Wolfson Institute of Preventive Medicine, Queen Mary University of London, London, United Kingdom.

<sup>4</sup> Department of Statistical Science, University College London, London, United Kingdom.

<sup>5</sup> Pathology Department, Central Hospital, Falun, Sweden.

<sup>6</sup> Cancer Control Sciences Department, American Cancer Society, Atlanta, Georgia.

Supported in part by the American Cancer Society through a gift from the Longaberger® Company.

The authors thank Peter Dean, Peter Sasieni, and Jack Cuzick for their helpful discussion and Ms. Inger Hermansson and Ms. Sara Hermansson for administrative assistance.

Address for reprints: Robert A. Smith, Ph.D., Cancer Control Department, American Cancer Society, 1599 Clifton Road Northeast, Atlanta, GA 30329; Fax: (404) 325-2548; E-mail: robert.smith@cancer.org

Received April 13, 2004; revision received July 12, 2004; accepted July 12, 2004

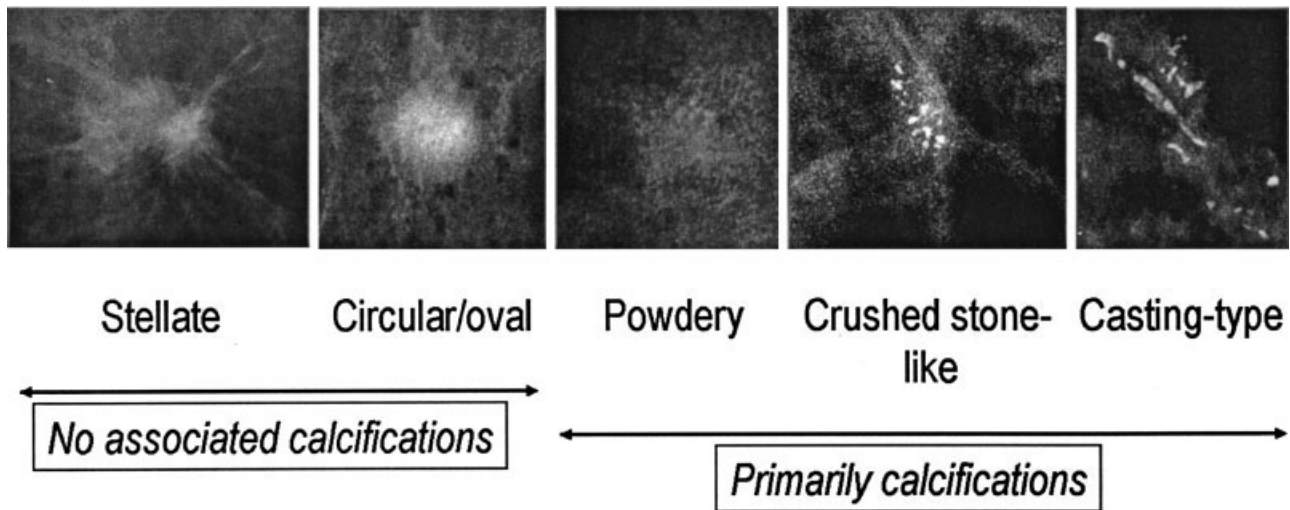
**BACKGROUND.** The radiologic images of 1–14-mm invasive breast carcinomas can be classified into 5 separate categories. The use of these mammographic indicators to predict patient outcome has important prognostic and therapeutic implications.

**METHODS.** To verify the results of previous studies conducted with smaller numbers of patients, the authors studied the 24-year survival of 714 women with 1–14-mm invasive breast carcinoma according to mammographic prognostic factors. The association of mammographic features with lymph node status, histologic malignancy grade, and 24-year survival in 714 women with invasive breast carcinomas that measured 1–14 mm also was evaluated. Adjustments were made for tumor characteristics and treatment factors in the survival analysis.

**RESULTS.** The most common mammographic feature was a stellate lesion with no associated calcifications (420 women; 59%). Patients with stellate lesions had excellent long-term survival (95%). Casting-type calcifications were observed in 52 women (7%) and were associated significantly with a positive lymph node status (odds ratio [OR], 3.29; 95% confidence interval [95% CI], 1.41–7.67), poorer histologic grade (OR, 7.04; 95% CI, 3.77–13.16), and an increased risk of death from breast carcinoma (HR, 9.19; 95% CI, 4.18–20.17). Except for women who had tumors with associated casting-type calcifications, all other women with tumors < 10 mm in size had excellent survival regardless of lymph node status, histologic grade, or treatment. For women who had casting-type calcifications, survival was poorer even in the group with tumors that measured 1–9 mm (72% at 20 years). For women with 10–14-mm tumors, the 20-year survival rate was 52% for those who had casting calcifications and 86–100% those for those who had other mammographic features.

**CONCLUSIONS.** The subgroup of women who had small invasive breast carcinomas accompanied by casting-type calcifications had an unexpectedly poor prognosis for this tumor-size category. The process of neoductogenesis offers a possible explanation for the unexpectedly poor outcome. There is a need to develop treatment protocols for this group and to reevaluate the present TNM classification system for mammographically detected 1–14-mm breast carcinomas. After excluding women who had tumors associated with casting-type calcifications, the remaining women had an extremely good prognosis when they were treated with surgery alone. Due to their already excellent survival, adjuvant therapeutic regimens are unlikely to offer further benefit for these patients. *Cancer* 2004;101:1745–59. © 2004 American Cancer Society.

**KEYWORDS:** casting-type calcifications, histologic grade, invasive breast carcinoma, lymph node status, stellate lesions, tumor attributes.



**FIGURE 1.** These photomicrographs show the appearance of mammographic features. All these samples were from histologically proven, 1–9 mm or 10–14 mm invasive breast carcinoma cases.

The correlation between mammographic appearance and long-term prognosis in patients with small invasive breast carcinoma, particularly for those with T1a and T1b tumors, has gained importance as mammography service screening programs detect these small tumors in ever increasing numbers. Despite the excellent prognosis for the majority of patients with small breast carcinomas, a small number of women still die from T1a and T1b tumors after long-term follow-up. Previous studies have suggested that the mammographic features of these small tumors may be used to predict the long-term outcome of patients with breast carcinoma successfully. Three studies have found that the presence of casting-type microcalcifications on a mammogram is a reliable predictor for poor prognosis in women with small invasive breast carcinomas.<sup>1–3</sup> One of those studies found a 20-year survival rate of only 55% for the subgroup of women who had 1–9-mm invasive breast carcinomas with associated casting-type calcifications, whereas the remaining women had a 95% 20-year survival rate.<sup>1</sup> Similar findings were observed by Peacock et al.,<sup>2</sup> Zunzunegui et al.,<sup>3</sup> and Thurfjell et al.,<sup>4</sup> although the latter study related to other types of calcifications in addition to the casting type. One study did not find an independent effect of the presence of casting-type calcifications on survival but noted a strong association of their appearance with poor histologic grade.<sup>5</sup>

Although the findings discussed above strongly support the association between mammographic appearance of invasive breast carcinomas and long-term outcome, the correlation between the so-called mam-

**TABLE 1**  
Numbers of Breast Carcinoma Deaths and Patients by Mammographic Appearance for Small Invasive Breast Carcinomas in Women Ages 40–69 Years

Mammographic appearance	Tumor size (mm)		
	1–9	10–14	1–14
Stellate without calcifications	1/154	12/266	13/420
Circular/oval without calcifications	2/66	8/101	10/167
Powdery calcifications ± without tumor mass	0/18	0/4	0/22
Crushed stone-like calcifications ± tumor mass	2/26	0/22	2/48
Casting-type calcifications ± tumor mass	6/32	9/20	15/52
Others	1/4	0/1	1/5
Total	12/300	29/414	41/714

±: with or without.

mographic prognostic factors and histologic tumor attributes, such as lymph node status and histologic grade, remains unclear. Furthermore, the independent effect of mammographic features on long-term outcome after adjustment for tumor attributes and treatment modality also is uncertain in previous studies because of small sample sizes. To address these issues, a large study focusing on mammographic appearance and long-term prognosis for women with 1–14-mm invasive breast carcinomas would be required. Such a study must address the logistic problems of long-term follow-up in the group of women with T1a, T1b, and 10–14-mm invasive breast carcinomas, who generally have very good survival. It also must elucidate whether the correlation between mam-

**TABLE 2**  
Distribution of Mammographic Appearance by Age Group and Tumor Size

Mammographic appearance	Tumor size (mm)											
	Women ages 40–49 yrs						Women ages 50–69 yrs					
	1–9		10–14		1–14		1–9		10–14		1–14	
	No.	%	No.	%	No.	%	No.	%	No.	%	No.	%
Stellate without calcifications	24	42.1	57	71.3	81	59.1	130	53.5	209	62.6	339	58.8
Circular/oval without calcifications	9	15.8	10	12.5	19	13.9	57	23.5	91	27.2	148	25.6
Powdery calcifications ± tumor mass	9	15.8	2	2.5	11	8.0	9	3.7	2	0.6	11	1.9
Crushed stone-like calcifications ± tumor mass	7	12.3	5	6.3	12	8.8	19	7.8	17	5.1	36	6.2
Casting-type calcifications ± tumor mass	8	14.0	6	7.5	14	10.2	24	9.9	14	4.2	38	6.6
Others	0	0.0	0	0.0	0	0.0	4	1.6	1	0.3	5	0.9
Totals	57	100.0	80	100.0	137	100.0	243	100.0	334	100.0	577	100.0

±: with or without.

**TABLE 3**  
The Association between Mammographic Appearance and Lymph Node Status

Mammographic appearance	Lymph node status		OR (95% CI)	
	Negative	Positive	Crude	Adjusted <sup>a</sup>
Stellate without calcifications	323	45	1.00	1.00
Circular/oval without calcifications	132	12	0.65 (0.34–1.27)	0.54 (0.26–1.11)
Powdery calcifications ± tumor mass	15	2	0.96 (0.21–4.33)	1.29 (0.22–7.54)
Crushed stone-like calcifications ± tumor mass	42	4	0.68 (0.23–2.00)	1.00 (0.32–3.08)
Casting-type calcifications ± tumor mass	35	12	2.46 (1.19–5.09)	3.29 (1.41–7.67)

OR: odds ratio; 95% CI: 95% confidence interval; ±: with or without.

<sup>a</sup> Adjusted for age, tumor grade, and tumor size in continuous scale.**TABLE 4**  
The Association between Mammographic Appearance and Histologic Grade

Mammographic appearance	Histologic tumor grade			OR (95% CI)	
	1	2	3	Crude	Adjusted <sup>a</sup>
Stellate without calcifications	202	175	36	1.00	1.00
Circular/oval without calcifications	72	62	33	1.51 (1.07–2.12)	1.57 (1.11–2.23)
Powdery calcifications ± tumor mass	17	3	2	0.31 (0.12–0.83)	0.72 (0.26–2.01)
Crushed stone-like calcifications ± tumor mass	14	29	4	1.84 (1.03–3.29)	2.29 (1.25–4.21)
Casting-type calcifications ± tumor mass	4	33	13	5.41 (2.99–9.78)	7.04 (3.77–13.16)

OR: odds ratio; 95% CI: 95% confidence interval; ±: with or without.

<sup>a</sup> Adjusted for age, lymph node status, and tumor size in continuous scale.

mammographic appearance and regional lymph node spread or histologic grade allows mammographic appearance to be used as a surrogate endpoint for long-term outcome.

The objective of the current study was to examine the correlation between mammographic features and long-term outcome based on a large, consecutive co-

hort of women with 1–14-mm invasive breast carcinomas. The associations of mammographic appearance with regional lymph node spread and histologic grade were studied. The independent associations between mammographic appearance and long-term prognosis, adjusted for tumor attributes and treatment modality, also were assessed.

**TABLE 5**  
Surgical Treatment Modality and Mammographic Appearance

Mammographic appearance	Mastectomy		BCS		Others		Total
	No.	%	No.	%	No.	%	
Stellate without calcifications	134	31.9	281	66.9	5	1.2	420
Circular/oval without calcifications	49	29.3	117	70.1	1	0.6	167
Powdery calcifications ± tumor mass	5	22.7	17	77.3	0	0.0	22
Crushed stone-like calcifications ± tumor mass	29	60.4	19	39.6	0	0.0	48
Casting-type calcifications ± tumor mass	35	67.3	13	25.0	4	7.7	52
Others	5	100.0	0	0.0	0	0.0	5
Total	257	36.0	447	62.6	10	1.4	714

BCS: breast-conserving surgery; ±: with or without.

**TABLE 6**  
Mammographic Appearance and Adjuvant Therapy

Mammographic appearance	RT only		CT only		T only		RT + CT		RT + T		RT + CT + T		None		Total
	No.	%	No.	%	No.	%	No.	%	No.	%	No.	%	No.	%	
Stellate without calcifications	101	66.9	0	0.0	3	2.0	4	2.6	12	7.9	1	0.7	30	19.9	151
Circular/oval without calcifications	45	77.6	1	1.7	0	0.0	2	3.4	3	5.2	0	0.0	7	12.1	58
Powdery calcifications ± tumor mass	6	75.0	0	0.0	0	0.0	0	0.0	0	0.0	0	0.0	2	25.0	8
Crushed stone-like calcifications ± tumor mass	7	43.8	0	0.0	0	0.0	0	0.0	1	6.3	1	6.3	7	43.8	16
Casting-type calcifications ± tumor mass	8	53.3	1	6.7	0	0.0	1	6.7	2	13.3	0	0.0	3	20.0	15
Others	0	0.0	0	0.0	0	0.0	0	0.0	0	0.0	0	0.0	2	100.0	2

RT: radiotherapy; CT: chemotherapy; T: tamoxifen; ±: with or without.

## MATERIALS AND METHODS

### Patients

Overall, 715 consecutive patients ages 40–69 years with 1–14-mm invasive breast carcinoma were diagnosed in Dalarna County, Sweden, between October 3, 1977 and December 31, 1998 and were followed through December 31, 2001. Mammograms from the Swedish Two-County Trial and the subsequent service screening program<sup>6,7</sup> were available for review in all but one patient. Thus, the analysis was based on the remaining 714 patients. Of these, 247 patients had been included in our previous study.<sup>1</sup> The tumors were categorized further according to size into 2 groups: 1–9 mm and 10–14 mm. Tumor size was based on a consensus between the radiologist, who measured the size of the invasive component on the specimen radiogram at the tumor board, and the judgment of the pathologist during histologic measurement, as well as on the large-section histology glass (10 cm × 8 cm). In the event of a discrepancy, the histologic tumor size was the final determinant.

### Tumor Classification by Mammographic Image, Histologic Characteristics, and Long-Term Outcome

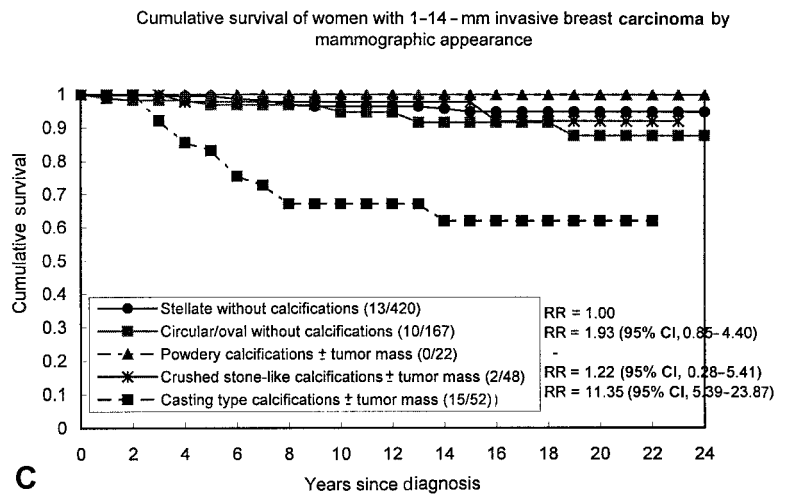
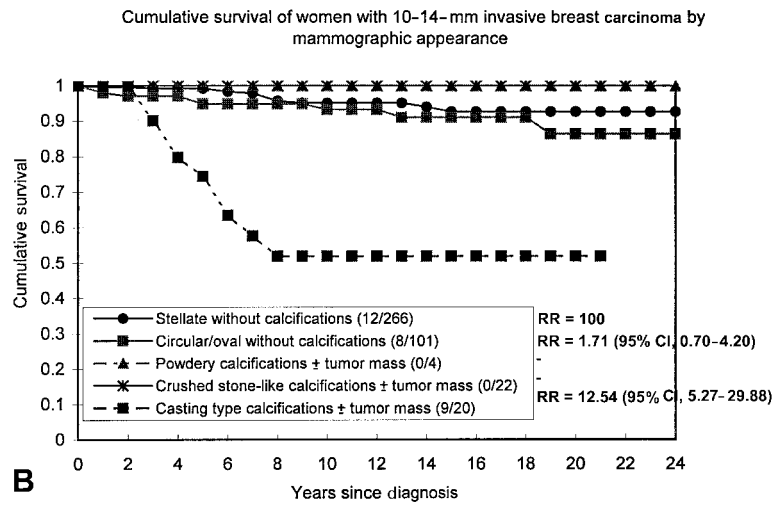
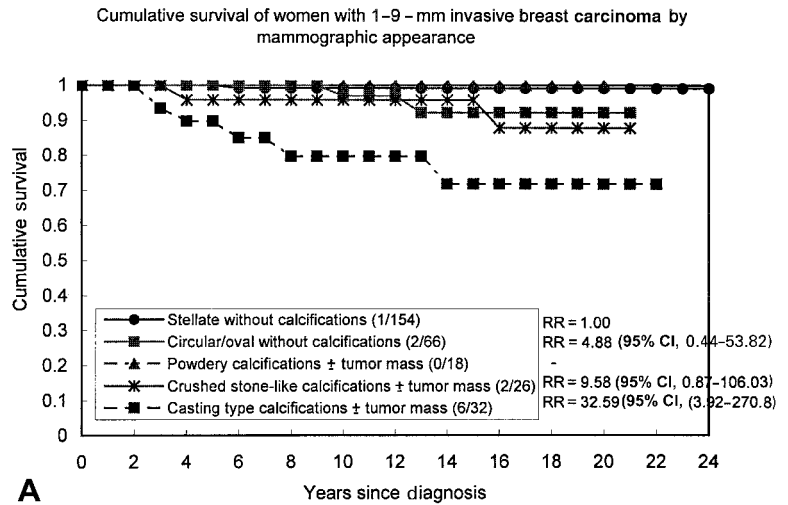
The mammographic appearance of the invasive tumors in the current study was classified as 1) stellate

without associated calcifications, 2) circular or oval-shaped mass without associated calcifications, 3) powdery calcifications with or without associated tumor mass on the mammogram, 4) casting-type calcifications with or without associated tumor mass, 5) crushed stone-like calcifications with or without associated tumor mass, and 6) others (e.g., galactographic findings, nonspecific asymmetric density). The major radiologic features are categorized readily (see Fig. 1).

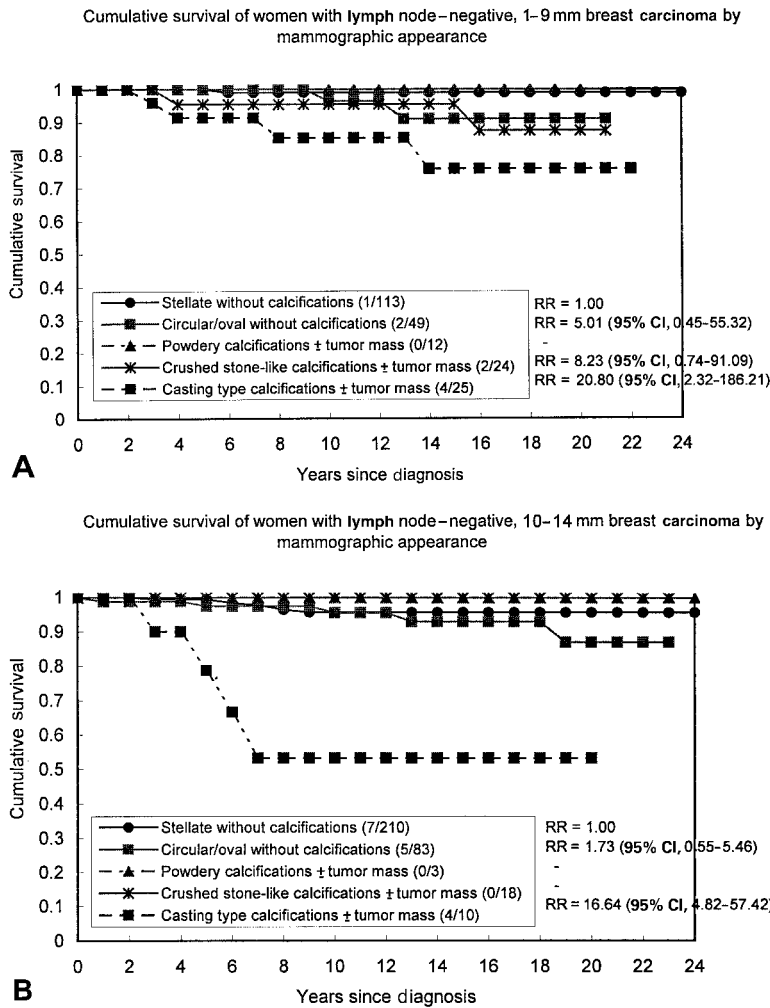
The recorded histologic tumor characteristics included tumor size, histologic grade (using the WHO grading system), and lymph node status. The choice of surgical treatment (breast-conserving surgery, mastectomy) and adjuvant treatment regimens (radiotherapy, chemotherapy, hormone therapy, or combinations of these) also were recorded. The outcome for each woman with breast carcinoma was determined as either death from breast carcinoma, death from other causes, or still alive at the end of follow-up.

### Statistical Methods

The association between mammographic feature and lymph node status, with or without adjustment for histologic grade, patient age, and tumor size, was analyzed using a multiple logistic regression model. Unadjusted



**FIGURE 2.** The effect of mammographic appearance on long-term prognosis. RR: relative risk; 95% CI: 95% confidence interval.



**FIGURE 3.** The effect of mammographic appearance and lymph node status on survival. RR: relative risk; 95% CI: 95% confidence interval.

and adjusted odds ratios (ORs) and their 95% confidence intervals (95% CIs) associated with lymph node positivity were estimated using logistic regression. The ORs for histologic grade were estimated using proportional odds regression.<sup>8</sup> To estimate the effect of mammographic appearance on long-term prognosis, the Cox proportional hazards model was used, adjusting for significant tumor attributes, such as lymph node status, histologic grade, or treatment modality.

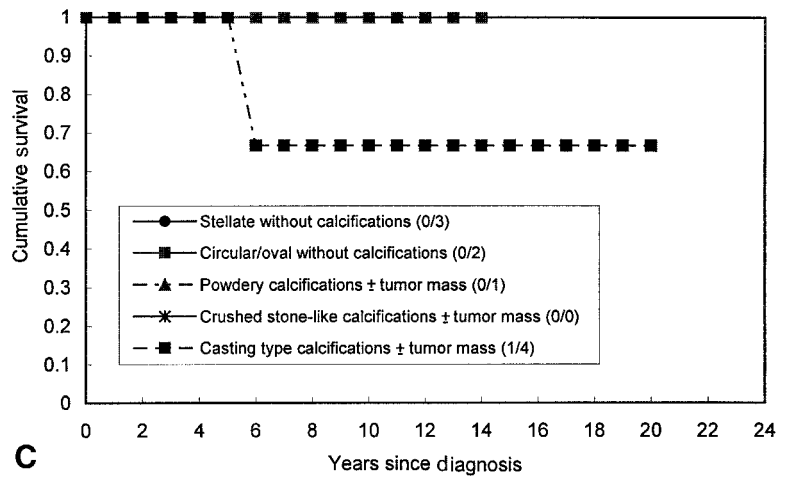
**RESULTS**

**Distribution of Mammographic Features**

Table 1 shows breast carcinoma deaths and numbers of patients by mammographic features and tumor size in the group of patients ages 40-69 years. Table 2 shows the distribution of mammographic features by tumor size in specific age groups: Women age < 50 years tended to have a greater proportion of masses with casting-type calcifications compared with women age > 50 years, although the difference was

not statistically significant ( $P = 0.14$ ). Circular or oval-shaped masses without associated calcifications were most common in the older women, whereas stellate masses without associated calcifications were distributed equally by age group. The younger women also were found to have greater proportions of powdery calcifications with or without an associated tumor mass. Overall, among tumors that measured 1-14 mm in greatest dimension, 59% were stellate without associated calcifications, 23% were circular or oval-shaped masses without associated calcifications, 3% had powdery calcifications with or without an associated tumor mass, 7% had crushed stone-like calcifications with or without mammographically demonstrable tumor mass, and 7% had casting-type calcifications. When they were subdivided further into tumor sizes 1-9 mm and 10-14 mm, the corresponding values were 51%, 22%, 6%, 9%, and 11% for tumors that measured 1-9 mm and 64%, 24%, 1%, 5%, and 5% for tumors that measured 10-14 mm, respectively.

Cumulative survival of women with lymph-node positive, 1–9 mm–breast carcinoma by mammographic appearance



Cumulative survival of women with lymph-node positive, 10–14 mm–breast carcinoma by mammographic appearance

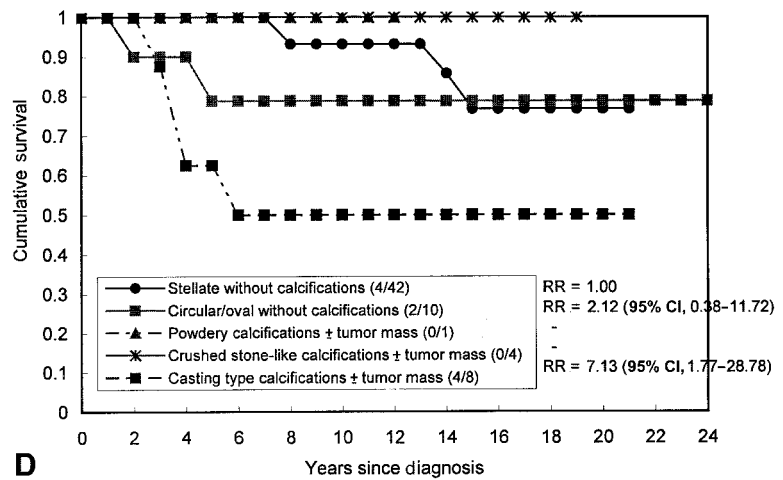
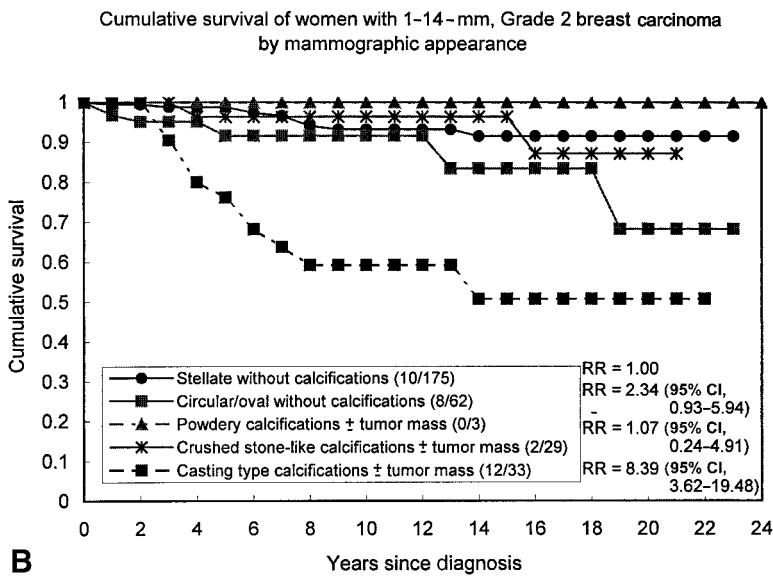
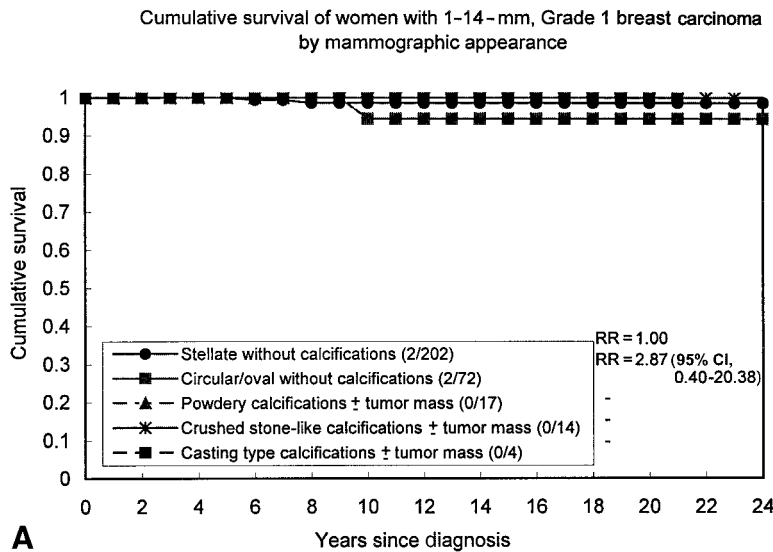


FIGURE 3. (continued)

**Tumor Attributes and Mammographic Features**

The correlations between mammographic appearance and regional lymph node spread and histologic grade are shown in Tables 3 and 4. Table 3 shows the ORs adjusted for age, histologic grade, and tumor size by inclusion of these factors in the logistic regression analysis. This was done to take account of any confounding by these factors. Similarly, in Table 4, estimates adjusted for age, lymph node status, and tumor size are shown. The OR for lymph node-positive disease with casting-type calcifications, relative to stellate lesions with no calcifications, was 3.29 (95% CI, 1.41–7.67) after adjusting for patient age, histologic grade, and tumor size. The corresponding values for circular or oval-shaped masses without associated calcification and for powdery calcifications or crushed

stone-like calcifications with or without an associated tumor mass were 0.54 (95% CI, 0.26–1.11), 1.29 (95% CI, 0.22–7.54), and 1.00 (95% CI, 0.32–3.08), respectively. Table 4 shows the association between mammographic appearance and histologic grade. After controlling for patient age, lymph node status, and tumor size as a continuous variable, the proportional OR for patients with casting-type calcifications was found to be 7-fold (OR, 7.04; 95% CI, 3.77–13.16) and highly statistically significant ( $P < 0.001$ ). It should be noted that this was due more to a preponderance of Grade 2 invasive tumors (66%) among patients who had casting-type calcifications rather than Grade 3 tumors (26%). Similar findings for casting-type calcifications were observed in separate subgroup analyses of the group with tumors that measured 1–9 mm in



**FIGURE 4.** The effect of mammographic appearance and histologic grade on survival. RR: relative risk; 95% CI: 95% confidence interval.

greatest dimension and the group with tumors that measured 10–14 mm in greatest dimension (data not shown).

**Correlation of Mammographic Features with Current Surgical Treatment and Adjuvant Therapy**

Tables 5 and 6 show surgical treatment modality and adjuvant therapy according to mammographic appearance. Prior to 1992, very little adjuvant therapy was used other than radiotherapy. Thus, for adjuvant therapy, data were available only for tumors that were diagnosed in the modern therapeutic era (1992–1998). Mastectomy was undergone by significantly greater proportions of women who had tumors with casting-type and crushed stone-like calcifications with or without an associated tumor mass on the mammo-

gram, largely due to extensive ductal carcinoma in situ (DCIS), frequent occurrence of tumor at the resection margin, and additional foci found at histologic evaluation.

**Long-Term Outcome Evaluation**

Table 1 shows the numbers of tumors and case fatalities by mammographic tumor characteristics and tumor-size categories. In the 1–14-mm size group, the women with casting-type calcifications were found to have the highest fatality rate (29%), followed by women with circular or oval-shaped masses without associated calcifications (6%), women with crushed stone-like calcifications with or without associated tumor mass (4%), and women with stellate lesions without associated calcifications (3%). The best outcome



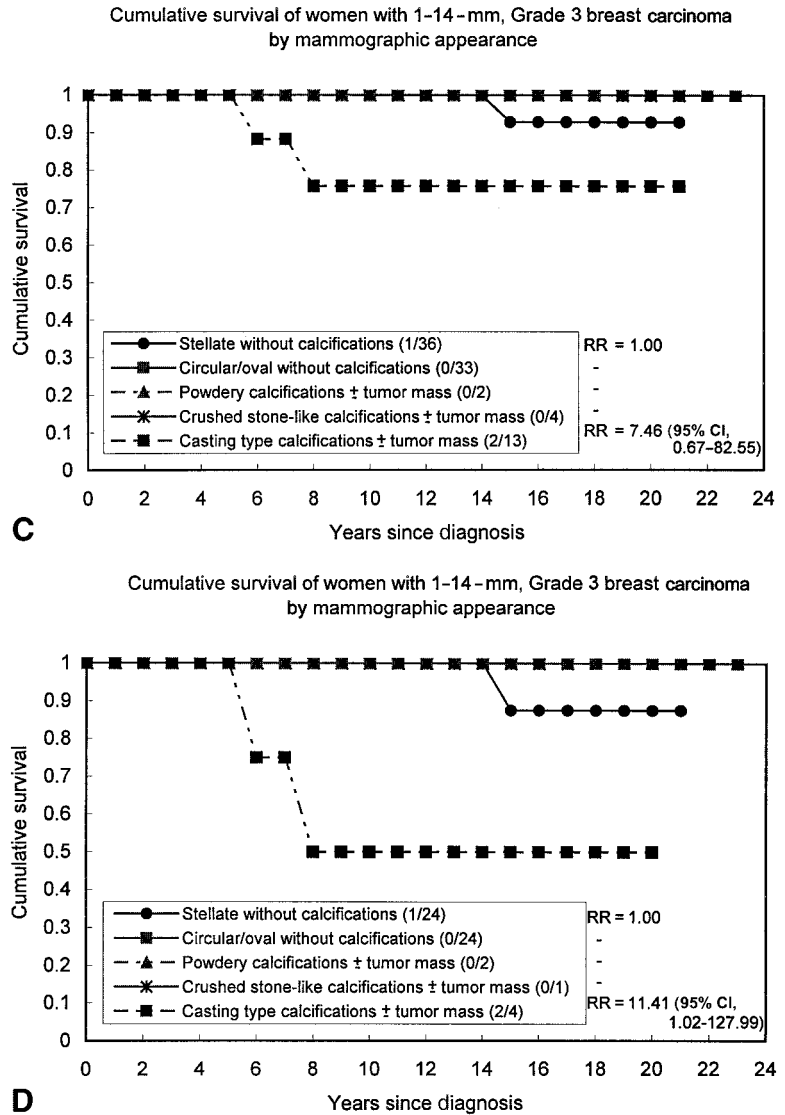


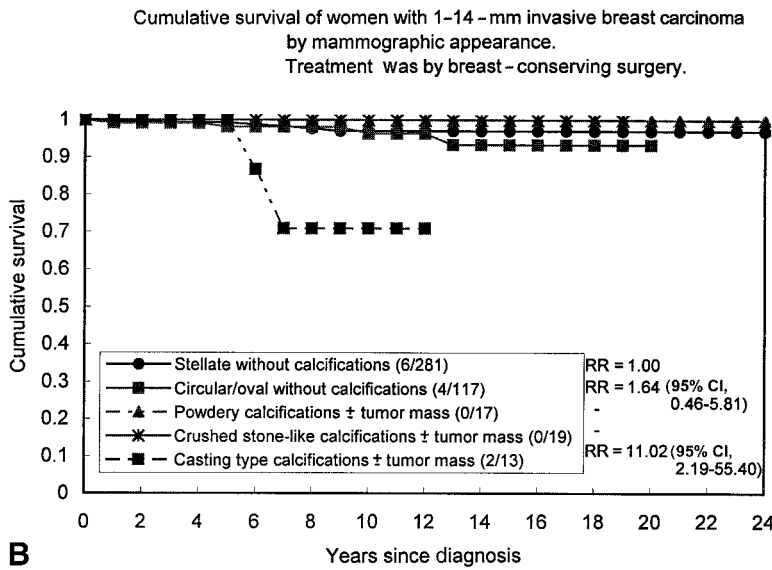
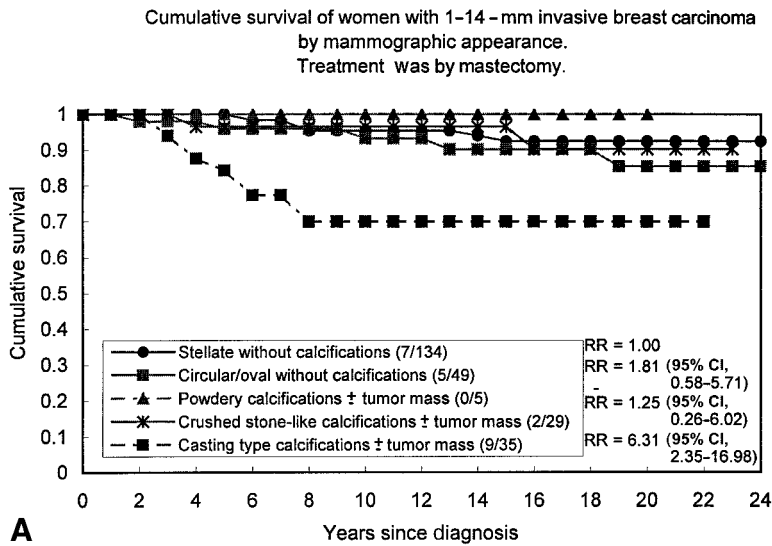
FIGURE 4. (continued)

was observed in the group of women who had powdery calcifications with or without associated tumor mass (0% fatality).

Figure 2A-C shows cumulative survival by mammographic appearance. The common feature of these 24-year survival curves is the strikingly poor survival of women who had casting-type calcifications compared with the excellent survival of women in all of the other mammographically classified groups. Women with 1-9-mm invasive tumors associated with casting-type calcifications had a > 30-fold increased risk (relative risk [RR], 32.59; 95% CI, 3.92-270.88) of dying from breast carcinoma adjusted for tumor size compared with women who had stellate lesions with no calcifications. The corresponding RR estimates were 12.54 (95% CI, 5.27-29.88) for tumors that measured 10-14 mm and 11.35 (95% CI, 5.39-23.87) for tumors in the

combined 1-14-mm size range. These differences in survival were highly statistically significant ( $P < 0.001$  in all analyses).

Figure 3 shows cumulative survival associated with mammographic appearance of the tumors by lymph node status and tumor size. Among all lymph node-negative, 1-9-mm tumors, only women who had casting-type calcifications had a poor prognosis (76% survival), and women who had tumors with all other mammographic features had 87-100% 20-24-year survival. Even with increasing tumor size, there was no deterioration in outcome observed in the women who had lymph node-negative tumors without casting-type calcifications. Women who had casting-type calcifications were found to have a poor prognosis irrespective of their lymph node status or tumor size. Among women who had circular and stellate tumors



**FIGURE 5.** The effect of mammographic appearance on cumulative survival by surgical treatment or adjuvant therapy. RR: relative ratio; 95% CI: 95% confidence interval.

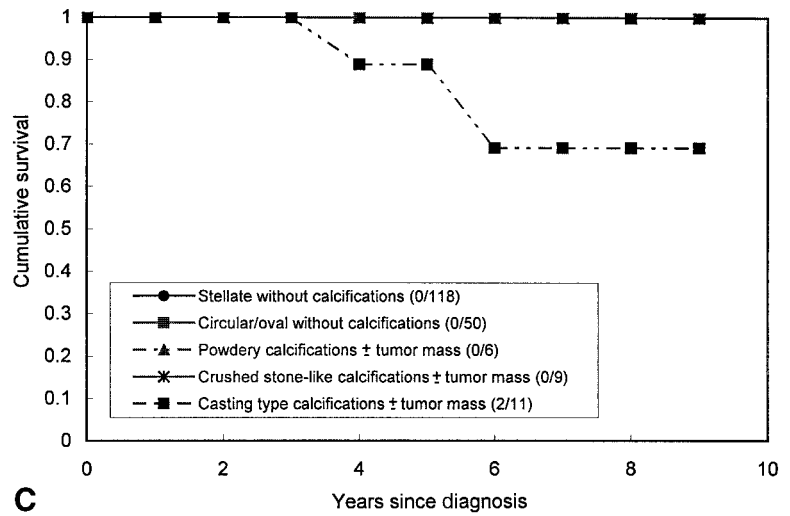
with no associated calcifications, positive lymph node status started to affect outcomes when the tumors measured > 10 mm in greatest dimension. There were very few lymph node-positive tumors that measured 1–9 mm (10 of 300 tumors).

Figure 4 shows the effect of the mammographic tumor appearance on survival by histologic grade. The poorer prognosis for women who had tumors with casting-type calcifications was noted for Grade 2 and 3 tumors, but not Grade 1 tumors. However, there were relatively few women who had casting-type calcifications in low-grade tumors. It is interesting to note that the effect of mammographic features on survival was more apparent than the effect of grade. The survival of women who had circular/oval tumors without calcifications, although it was much better than the survival of women who had casting-type calcifications, was

slightly poorer compared with the survival of women who had Grade 2 tumors in the other mammographic categories. Among the 10–14-mm Grade 3 tumors, the poorer survival of women who had casting-type calcifications was much more pronounced.

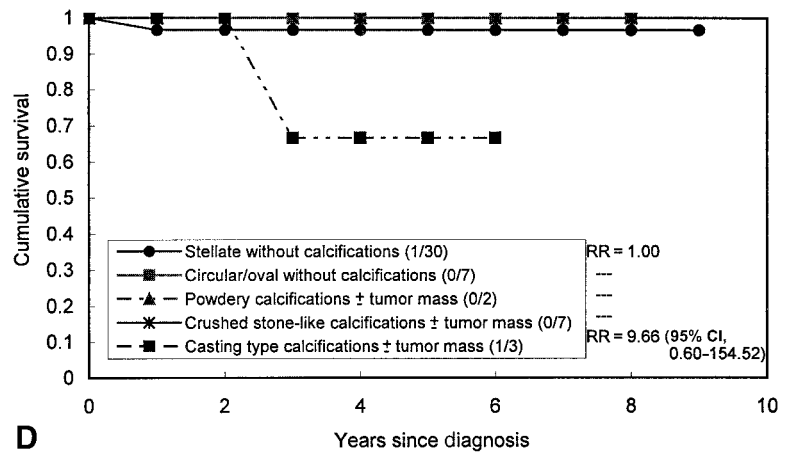
Figure 5 shows the cumulative survival curves for mammographic appearance by surgical treatment and radiotherapy. There was shorter follow-up for these patients due to the fact that we had information regarding treatment only for tumors that were diagnosed between 1992 and 1998. Those women who had tumors with associated casting-type calcifications were found to have poor survival regardless of the type of surgical treatment or postoperative radiotherapy, regardless of whether they received any adjuvant therapy. Women who had circular or oval-shaped masses without calcifications and had received radiotherapy

Cumulative survival of women with 1–14–mm invasive breast carcinoma who were treated with radiotherapy by mammographic appearance



C

Cumulative survival of women with 1–14–mm invasive breast carcinoma without treatment of radiotherapy, chemotherapy, or tamoxifen by mammographic appearance



D

FIGURE 5. (continued)

or undergone breast-conserving surgery had intermediate survival rates. Women who had tumors in other categories were reported to have very good 24-year survival, regardless of the treatment modality chosen.

Table 7 shows the results of multiple proportional hazards regression of mammographic features of breast carcinoma and treatment adjusted for each other, with hazard ratios (HR) and 95% CIs. Tumors with casting-type calcifications still were associated with substantially poorer survival after adjustment for treatment factors. It should be noted that, because these are small tumors, few patients received any adjuvant treatment other than radiotherapy: hence the wide 95% CIs.

Table 8 shows the results of multiple Cox regres-

sion analysis for assessment of the impact of mammographic features of breast carcinomas on long-term prognosis after adjustment for lymph node status, histologic grade, and tumor size. To have sufficient deaths for estimation in each category, some categories with similar long-term outcome have been combined. After this adjustment, the risk of dying from breast carcinoma was found to be statistically significantly higher by a factor of 9 for women who had tumors associated with casting-type calcifications, compared with women who had stellate tumors without associated calcifications (RR, 9.19; 95% CI, 4.18–20.17). The only other mammographic category with an elevated risk of dying from breast carcinoma was the circular/oval tumors, but this did

**TABLE 7**  
The Effect of Mammographic Appearance on Breast Carcinoma Death, Making Allowance for Surgical Treatment and Adjuvant Therapy

Factor/category	HR	95% CI
Mammographic appearance		
Noncasting	1.00	—
Casting calcifications	27.59	2.28–333.95
Surgical treatment		
None or others	1.00	—
Mastectomy	0.05	0.002–1.28
Breast-conserving surgery	0.08	0.003–1.99
Adjuvant therapy		
None	1.00	—
Radiotherapy	0.37	0.03–4.59
Chemotherapy	3.68	0.18–73.70
Hormone therapy	4.93	0.19–126.52

HR: hazard ratio; 95% CI: 95% confidence interval.

**TABLE 8**  
Relative Hazard Ratios and 95% Confidence Intervals from Multivariate Cox Regression Analysis Incorporating Tumor Size, Lymph Node Status, Histologic Tumor Grade, and Mammographic Appearance Mutually Adjusted

Factor/category	HR	95% CI
Tumor size		
1–9 mm	1.00	—
10–14 mm	2.05	1.01–4.18
Lymph node status		
Negative	1.00	—
Positive <sup>a</sup>	1.95	1.00–3.78
Histologic tumor grade		
Grade 1	1.00	—
Grade $\geq 2^b$	4.62	1.63–13.15
Mammographic appearance		
Stellate without calcifications	1.00	—
Circular/oval without calcifications	1.88	0.82–4.30
Casting-type calcifications	9.19	4.18–20.17
Others	1.41	0.40–4.98

HR: hazard ratio; 95% CI: 95% confidence interval.

<sup>a</sup> Includes patients with unknown lymph node status, because this group had similar survival to that of the group with positive lymph node status.

<sup>b</sup> Includes patients with unknown histologic tumor grade, because this group had similar survival to that of the group with Grade 2 and 3 tumors.

not quite reach statistical significance (RR, 1.88; 95% CI, 0.82–4.30). There were two nonsignificant but suggestive interactions in the Cox regression between tumor size and lymph node status and between tumor size and histologic grade. The poorer survival among women who had 10–14-mm tumors was confined to those with positive lymph node status and those with Grade  $\geq 2$  tumors.

The implications of the multivariate model can be seen more clearly in Table 9, which shows the fitted

**TABLE 9**  
Twenty-Year Percentage Survival to Death from Breast Carcinoma Estimated from the Multivariate Cox Regression Model by Tumor Size, Lymph Node Status, Histologic Tumor Grade, and Mammographic Appearance

Lymph node status/mammographic appearance	Tumor size (mm)	
	1–9	10–14
Negative		
Grade 1		
Stellate, no calcifications	98	99
Circular/oval, no calcifications	97	97
Casting type calcifications	84	90
Others	98	98
Grade $\geq 2$		
Stellate, no calcifications	96	92
Circular/oval, no calcifications	92	85
Casting type calcifications	67	47
Others	94	89
Positive		
Grade 1		
Stellate, no calcifications	98	97
Circular/oval, no calcifications	96	95
Casting type calcifications	83	77
Others	97	96
Grade $\geq 2$		
Stellate, no calcifications	95	83
Circular/oval, no calcifications	91	70
Casting-type calcifications	65	18
Others	94	77

20-year survival rates from the multivariate Cox model. Among women who had 1–9-mm tumors without casting-type calcifications, the 20-year fitted survival rate invariably was in excess of 90%, regardless of lymph node status or histologic grade. For women who had 1–9-mm, Grade 1 and Grade  $\geq 2$  tumors with casting-type calcifications, the survival rates were 83–84% and 65–67%, respectively. For women who had Grade 1, 10–14-mm tumors, the survival rate was  $> 90\%$ , except for those who had casting-type calcifications (77–90%, depending on lymph node status). For women who had 10–14-mm, lymph node-negative, tumors of Grade  $\geq 2$ , the survival rate was in excess of 80%, except for those who had casting-type calcifications (47% survival rate). For women who had 10–14-mm, lymph node-positive tumors, the survival rate was  $\approx 80\%$ , except for those who had circular/oval tumors with no calcifications (70%) and those who had casting-type calcifications, who had a very poor fitted survival rate of 18%.

Table 9 shows that, among women who had 1–9-mm tumors without casting calcifications, the predictive value of histologic grade and lymph node status for survival simply was not present; and, among women who had in 10–14-mm tumors, the predictive

value for long-term survival still was considerably smaller than the predictive value of the presence of casting-type calcifications. The survival of women with 10–14-mm tumors was only noticeably poorer than the survival of women with 1–9-mm tumors when casting calcifications also were present or when the tumor was Grade  $\geq 2$ . Overall, in tumors that measured 1–14 mm, mammographic features were the clearest predictor of survival followed by histologic grade, tumor size, and lymph node status.

## DISCUSSION

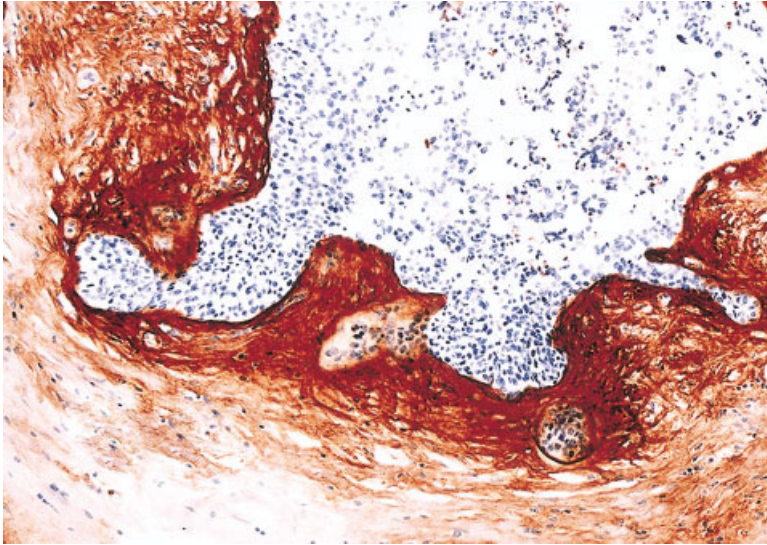
In this study, we assessed the role of mammographic features of breast carcinoma as an independent predictor of long-term outcome among women with 1–14-mm invasive breast carcinomas, adjusting for tumor attributes and treatment modality. To the best of our knowledge, the current study has been the largest to date addressing the association between mammographic features of these small breast carcinomas and their histologic tumor characteristics. We found that the mammographic tumor features can serve successfully as independent predictors for long-term outcome. On one hand, there was a single mammographic category of tumors, those associated with casting-type calcifications, which carried an unexpectedly poor long-term prognosis that was not found with any other risk factor in this size range. Conversely, women who had tumors with other mammographic features were found to have excellent 24-year survival, independent of lymph node status or histologic grade in the 1–9-mm size category. These observations strongly suggest the need to take the mammographic features of 1–14-mm, small breast carcinomas into account when planning patient treatment.

All women with 1–9-mm tumors, except for the small group associated with casting-type calcifications, appear to have an excellent 24-year survival without extensive surgery or any adjuvant treatment. In women with 10–14-mm tumors, the treatment consideration for tumors without associated casting-type calcifications should take the lymph node status and histologic grade into account. With regard to the treatment of women with 1–14-mm invasive tumors associated with casting-type calcifications, the results of the current study demonstrated poor survival irrespective of the therapeutic regimens that had been chosen. Further clarification of the effect of the various therapeutic regimens on this special group could be obtained from adjuvant therapy trials by retrospective analysis of the available mammograms. Another approach would be to design and perform a prospective, multicenter trial comparing various adjuvant therapeutic regimens.

The poorer prognosis for women who had tumors with casting-type calcifications was consistent with most of the published literature on the subject,<sup>1–4</sup> including correlations observed between a poorer prognosis associated with worse histologic grade<sup>5</sup> (including high-grade DCIS).<sup>9,10</sup> Casting calcifications also have been associated strongly with the risk of local recurrence.<sup>11</sup>

The long-term survival rates among women with 1–9-mm and 10–14-mm invasive breast carcinomas were 72.0% and 52.0%, respectively, when associated with casting-type calcifications that represented high-grade DCIS. These poor survival rates are similar to the rates reported among women with 30–49-mm, Grade 2, lymph node-negative, invasive ductal carcinomas; 20–29-mm, lymph node-positive, Grade 2, invasive ductal carcinoma; 20–29-mm, lymph node-negative, Grade 3, invasive ductal carcinoma; and 15–19-mm, lymph node-positive, Grade 3, invasive ductal carcinoma.<sup>1</sup> Conversely, the long-term survival rates among women with 1–9-mm and 10–14-mm invasive breast carcinomas *without* associated casting-type calcifications were found to be 95.0% and 91.0%, respectively. The basic morphologic difference between these two groups (which may explain the astounding difference in long-term outcome) is the presence of extensive, high-grade DCIS. Study of large-section, submacroscopic histologic images of these tumors demonstrates an unexpectedly large number of oddly shaped, carcinoma-filled ducts in a highly contorted arrangement (Fig. 6).

Tenascin (tenascin-C) overexpression is detectable around these ducts by using immunohistochemical stains, indicating an epithelial-stromal interaction similar to what occurs during the development of the duct system. In the current study, tenascin-C overexpression occurred periductally in all patients with Grade 3 DCIS, although the intensity varied. In the study by Jahkola et al., the corresponding prevalence of this overexpression was 87%.<sup>12</sup> We propose that this process of neoductogenesis represents a special type of neoplasia that generates a large volume of neoplastic tissue, as observed directly on large-section histology images and indirectly by the presence of extensive casting-type calcifications on mammograms. It appears that vascular intrusion may occur during the process of neoductogenesis, leading to the histologically demonstrable, extensive lymphatic and/or hematogenous spread. This morphologically *in situ* neoplastic process actually may behave as an invasive breast carcinoma with a large tumor burden, which likely accounts for the observed high fatality rates in patients with these tumors.



**FIGURE 6.** Tenascin overexpression is observed in the stroma surrounding the neoplastic duct (immunohistochemical reaction; original magnification,  $\times 200$ ).

The findings discussed earlier suggest that tumors with a size that normally would categorize them as T1a or T1b, but that are accompanied by casting-type calcifications, actually are not homogeneous with the general population of tumors of this size. The greater tumor burden, as evidenced by their clinical behavior, strongly suggests that they belong in a separate, more advanced-stage category. Inasmuch as staging categories imply an inherent similarity for the purposes of estimating prognosis and guiding therapy, the findings of the current study suggest the need to rethink tumor classification as well as therapy for women with breast carcinomas that have these mammographic appearances.

We also found that the distribution of mammographic features of breast carcinoma varied with age. The same proportions of stellate lesions without calcifications were observed in both age groups. There was a greater proportion of circular/oval-shaped tumors without associated calcifications in women age  $> 50$  years, whereas tumors associated with casting-type calcifications appeared to occur more frequently in women age  $< 50$  years. This finding is consistent with the previous results, which indicated that younger age was related to a poor prognosis among women with T1a and T1b tumors.<sup>13</sup> The question arises whether tumors with casting-type calcifications are associated with genetic markers, such as the *BRCA1* genotype, *HER-2/neu* overexpression, and the absence of hormone receptor.

The results of the current study indicate that mammographic features of breast carcinoma are predictive of a long-term risk of breast carcinoma death independently among women with 1–14-mm invasive

breast carcinomas. The mammographic features of tumors measuring 1–14 mm are more predictive of long-term survival than tumor size, lymph node status, or histologic grade. The vast majority of patients with 1–14-mm tumors do not have associated casting-type calcifications and have excellent long-term outcomes. However, patients with small invasive tumors associated with casting-type calcifications appear to have a poor prognosis. Therefore, there is an urgent need to develop effective treatment protocols for this particular subgroup.

When we originally described our observations regarding the prognostic value of mammographic features in predicting patient outcomes, we concluded that our findings were preliminary but nonetheless thought provoking with respect to the current inability to identify which women diagnosed with small breast carcinomas truly needed adjuvant therapy.<sup>1</sup> We strongly encouraged others to examine their material to determine whether our findings were reproducible, and we also encouraged the initiation of prospective therapy trials. Four years later, as outlined above, our findings have been confirmed by three other investigations and by our own extended material.<sup>2–4</sup> The longer term follow-up provides additional confirmation of the reliability of the mammographic signs to predict prognosis. In our judgment, the 99% 24-year survival rate among women with 1–9 mm stellate lesions, the most frequently occurring lesion, provides compelling evidence that there is little potential for adjuvant therapy or radical surgery to improve further on this excellent survival. Insofar as  $\geq 55\%$  of screen-detected invasive breast carcinomas are in the 1–14 mm size range, we hope our findings will stimulate

further research and discussion among leaders in breast care.

## REFERENCES

1. Tabar L, Chen HH, Duffy SW, et al. A novel method for prediction of long-term outcome of women with T1a, T1b, and 10–14 mm invasive breast cancers: a prospective study. *Lancet*. 2000;355:429–433.
2. Peacock C, Given-Wilson RM, Duffy SW. Mammographic casting type calcification associated with small screen-detected invasive breast cancers: is this a reliable prognostic indicator? *Clin Radiol*. 2004;59:165–170.
3. Zunzunegui RG, Chung MA, Oruwari J, Golding D, Marchant DJ, Cady B. Casting-type calcifications with invasion and high-grade ductal carcinoma in situ: a more aggressive disease? *Arch Surg*. 2003;138:537–540.
4. Thurfjell E, Thurfjell MG, Lindgren A. Mammographic finding as a predictor of survival in 1–9 mm invasive breast cancers, worse prognosis for cases presenting as calcifications alone. *Breast Cancer Res Treat*. 2001;67:177–180.
5. James JJ, Evans AJ, Pinder SE, Macmillan RD, Wilson AR, Ellis IO. Is the presence of mammographic comedo calcification really a prognostic factor for small screen-detected invasive breast cancers? *Clin Radiol*. 2003;58:54–62.
6. Tabar L, Fagerberg G, Duffy SW, Day NE, Gad A, Grontoft O. Update of the Swedish two-county program of mammographic screening for breast cancer. *Radiol Clin North Am*. 1992;30:187–210.
7. Tabar L, Yen MF, Vitak B, Chen HH, Smith RA, Duffy SW. Mammography service screening and mortality in breast cancer patients: 20-year follow-up before and after introduction of screening. *Lancet*. 2003;361:1405–1410.
8. McCullagh P. Regression models for ordinal data. *J R Stat Soc B*. 1980;42:109–127.
9. Holland R, Hendriks JH. Microcalcifications associated with ductal carcinoma in situ: mammographic-pathologic correlation. *Semin Diagn Pathol*. 1994;11:181–192.
10. Lagios MD, Margolin FR, Westdahl PR, Rose MR. Mammographically detected duct carcinoma in situ. Frequency of local recurrence following tylectomy and prognostic effect of nuclear grade on local recurrence. *Cancer*. 1989;63:618–624.
11. Malik HZ, Wilkinson L, George WD, Purushotham AD. Pre-operative mammographic features predict clinicopathological risk factors for the development of local recurrence in breast cancer. *Breast*. 2000;9:329–333.
12. Jahkola T, Toivonen T, Nordling S, von Smitten K, Virtanen I. Expression of tenascin-C in intraductal carcinoma of human breast: relationship to invasion. *Eur J Cancer*. 1998;34:1687–1692.
13. Dubsky PC, Gnant MF, Taucher S, et al. Young age as an independent adverse prognostic factor in premenopausal patients with breast cancer. *Clin Breast Cancer*. 2002;3:65–72.